

# Principle of Laparoscopic Port Position

## Dr R K Mishra

Professor and Head of Minimal Access Surgery, TGO University, India  
First University Qualified Master Minimal Access Surgeon of India (M.MAS)  
Editor in Chief World Journal of Laparoscopic Surgery (WJOLS)  
Member World Association of Laparoscopic Surgeon (WALS)  
Member European Association for Endoscopic Surgery (EAES)  
Member European Association for Transluminal Surgery (EATS)  
Member Society of American Gastrointestinal and Endoscopic Surgeons (SAGES)  
Member Society of Laparoendoscopic Surgeons (SLS)  
Member Society of Robotic Surgery (SRS)  
Member Clinical Robotic Surgery Association (CRSA)  
Member Association of Surgeons of India (ASI)  
Member Indian Medical Association (IMA)  
President All India Specially Abled Association (AISAA)  
Member Indian Association of Gastrointestinal Endosurgeons (IAGES)  
Chairman, Delhi Laparoscopy Hospital, Pvt. Ltd. & Director, World Laparoscopy Hospital, Gurgaon

The relative position of the instrument ports is very important in the performance of surgical procedures endoscopically. The angle the instruments make with the operative site and to each other should mimic, as far as possible to the natural relationship of the hands and eyes during conventional surgery. It is proved that the most common cause of stressful minimal access surgery is wrong port position. Ninety five percent of surgeon and gynecologists use umbilicus as primary port but at the time of inserting secondary port there is controversy among operator and they lack the principles behind secondary port position.

### **PRIMARY PORT POSITION**

The central location and ability of the umbilicus to camouflage scars makes it an attractive primary port site for laparoscopic surgery. There are many drawbacks with umbilicus as well. Umbilicus is a naturally weak area due to absence of all the layers. Weakness is also due its location at the midpoint of the abdomen's greatest diameter.

It is easy to believe that there is a difference between the umbilicus and other trocar sites in both susceptibility to infection and postoperative incisional herniation.

The study showed that the increased infection rate at the umbilicus seems to be related to retrieval of infected organs through the umbilicus and not to the umbilicus itself. When umbilicus was used to retrieve gallbladder after cholecystectomy the rate of infection was high due to port contamination with infected gallbladder. Excluding cholecystectomy, the umbilical infection rate was two percent, similar to that of any alternative site. The postoperative ventral hernia rate was at 0.8 percent, the same at the umbilicus as elsewhere if the port more than 10 mm size is not repaired. It is now proved that the wound infection at the umbilicus is similar to that at other sites; postoperative ventral hernia at the umbilicus is similar to that at other sites and most of the infection after laparoscopic cholecystectomy is due to the contamination of wound due to infected gallbladder.

### **SECONDARY PORT POSITION**

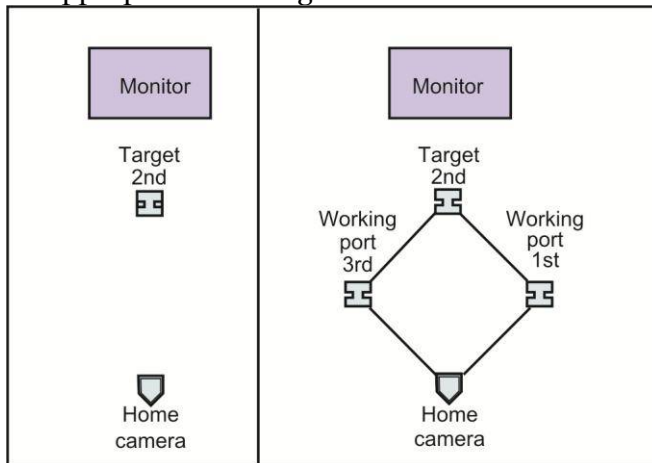
The obligatory passage of the laparoscopic instruments through the abdominal wall generates a fixed point after which all movements are reversed. For instance, when the hand moves to the left, the end of the instruments moves right, and when the hand moves downwards, the end of the instrument moves upwards. For some surgeon's the fulcrum effect is not a problem, but for others it is an insurmountable obstacle to the performance of advanced laparoscopy.

Because the handling of laparoscopic instruments is through the fixed point at abdominal wall, the force feedback felt by the surgeon will depend on the length of the instrument inferior to this fixed point.

### Base Ball Diamond Concept of Port Position

A satisfactory relationship includes (Fig. 6.1):

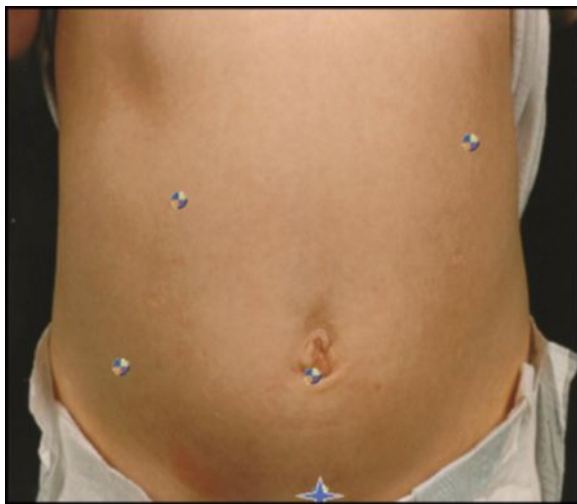- An angle of 60° between the two instrument tips
- Tangential approach to the site
- Appropriate working distance



**Fig. 6.1:** Base ball diamond concept of port position

### FIRST DECIDE THE TARGET

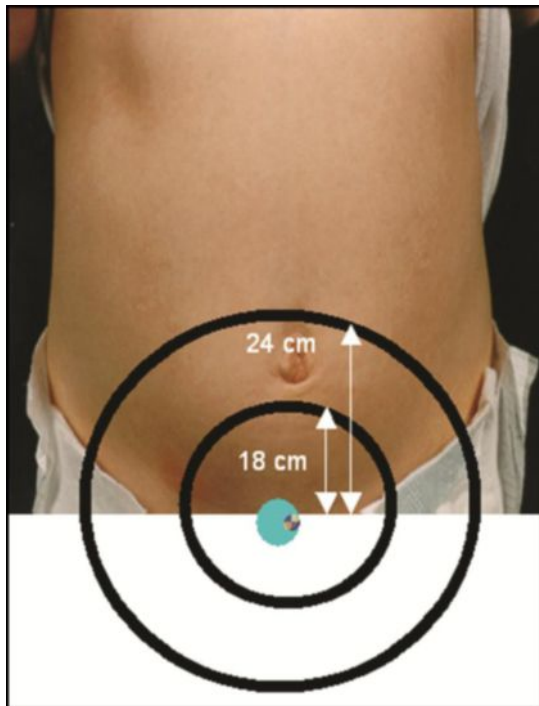
Target may be in suprapubic region for LAVH, right iliac fossa for appendicectomy, right upper quadrant for laparoscopic cholecystectomy or left upper quadrant for fundoplication (Fig. 6.2).\_\_




**Fig. 6.2:** First, decide the target

### Draw the Line of Optimum Area

For optimum task performance, half to two-third instrument should be inside the abdomen. The size of adult laparoscopic instrument is 36 cm and pediatrics instrument is 28 cm (Figs 6.3 and 6.4).



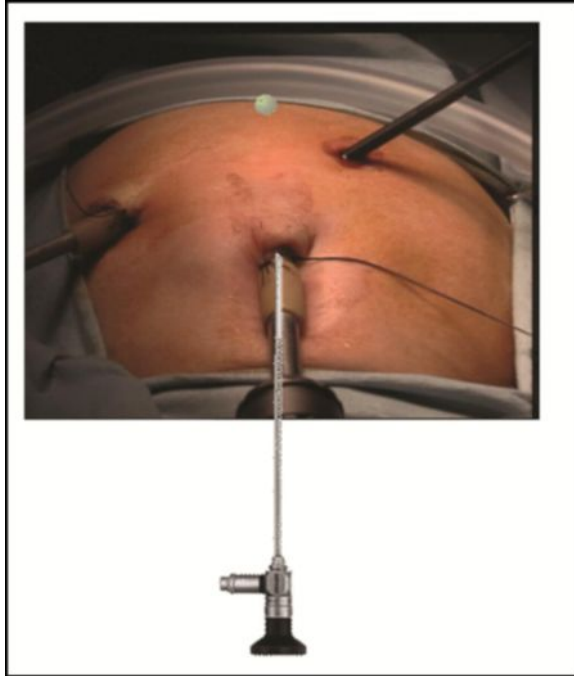
**Fig. 6.3: Draw two arcs on the abdominal wall at 18 and 24 cm from that point and note area in between**



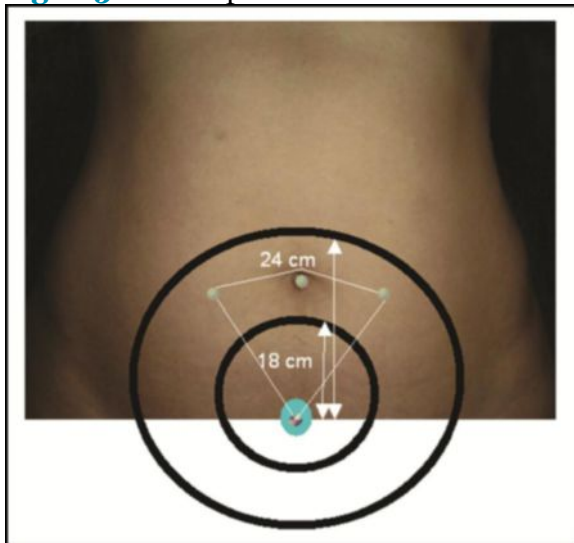
**Fig. 6.4: Measure the length of instrument**

### Telescope and Instruments

- Telescope should be in the middle of working instrument (Figs 6.5)



**Fig. 6.5:** Telescope should be in the center of working instrument



**Fig. 6.6:** 18 cm and 24 cm arc should be drawn

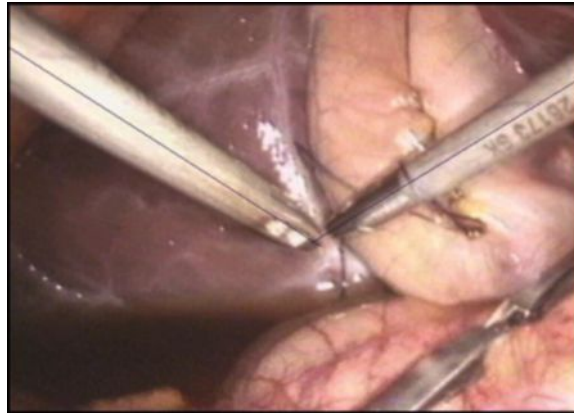
- Manipulation angle of instruments should be 60 degree (Fig. 6.7).

### Rule of Diamond for LAVH

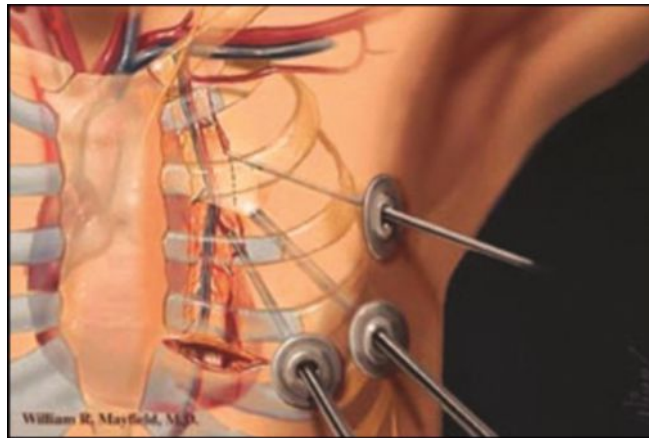
These factors combined with the specific anatomy will determine individual port sites. For standard operations like cholecystectomy, standard port sites related to surface marking may suffice but as more advanced or varied situations are tackled we recommend that you master the skill of individual port placement using the internal view. In general, the optic and the two main

operating ports usually lie at the points of a flattened triangle, the optic being centrally and more distally placed. Try to keep ports at least 5 cm apart (Figs 6.6 and 6.8).

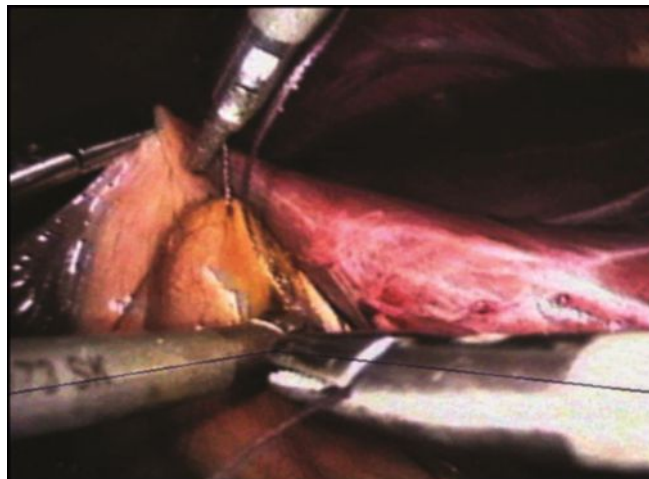
Manipulation angle 60° is essential for optimum task performance in laparoscopic surgery (Figs 6.7 and 6.9). 6.7



**Fig. 6.7:** Manipulation angle 60° is angle between tips of instrument

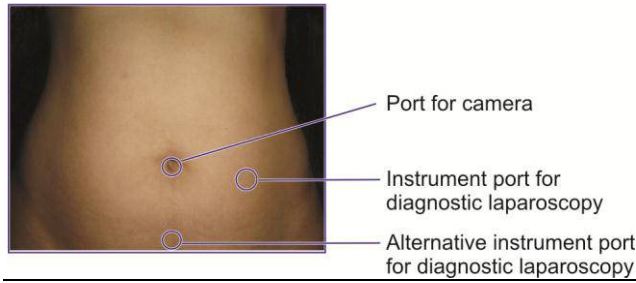


**Fig. 6.8:** Port position in thoracoscopic surgery

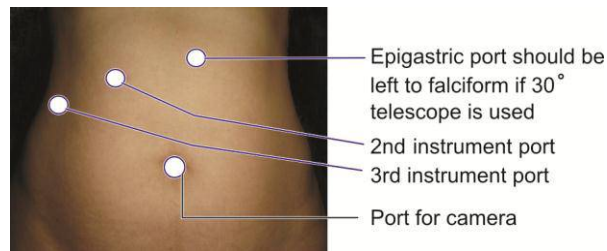


**Fig. 6.9:** Manipulation angle of 60° is ideal

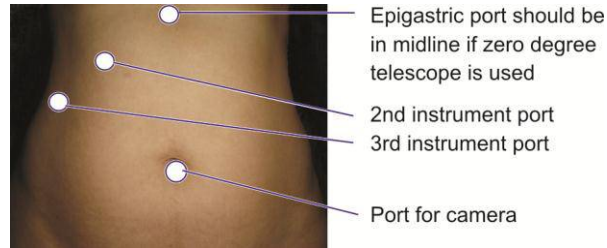
**PORT POSITION IN VARIOUS SURGERIES  
(FIGS 6.10 TO 6.14)**



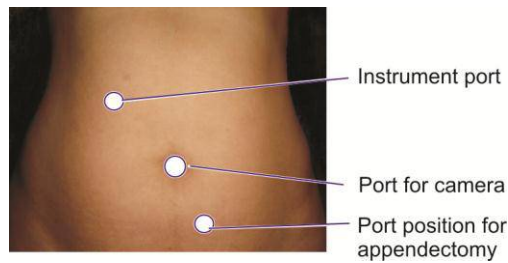
**Fig. 6.10:** Port position for diagnostic laparoscopy



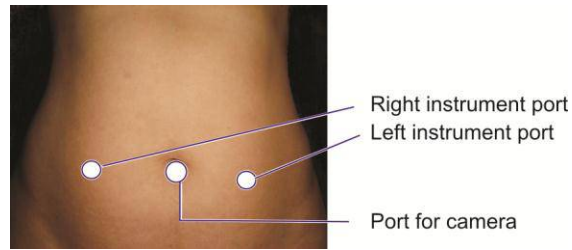
**Fig. 6.11:** Port position for cholecystectomy



**Fig. 6.12:** Alternative port position for cholecystectomy



**Fig. 6.13:** Port position for appendectomy



**Fig. 6.14:** Position for bilateral hernia, LAVH and most of the gynecological procedures

## **DRAWBACKS OF INCORRECT PORT POSITION**

### **Swording**

Swording occurs when the telescope or the shaft of the assistant's instrument obstruct the operator's instruments. If this occurs you may need to consider:

- Repositioning retracting instruments
- Rotation of an angled telescope allowing alteration of the position of the end of the telescope
- Withdrawal of the telescope
- Transposition of the operator's instruments
- Additional port placement
- Changing the instruments to a different port.

## **BIBLIOGRAPHY**

1. Abu-Rafea B, Vilos GA, Vilos AG, Ahmad R, Hollett-Caines J, Al Omran M. High-pressure laparoscopic entry does not adversely affect cardiopulmonary function in healthy women. *J Minim Invasive Gynecol* 2005;12(6):475-9.
2. Abu-Rafea B, Vilos GA, Vilos AG, Hollett-Caines J, Al Omran M. Effect of body habitus and parity on insufflated CO<sub>2</sub> volume at various intraabdominal pressures during laparoscopic access in women. *J Minim Invasive Gynecol* 2006;13(3):205-210.
3. Agresta F, De Simone P, Ciardo LF, Bedin N. Direct trocar insertion vs Veress needle in nonobese patients undergoing laparoscopic procedures: a randomized prospective single-center study. *Surg Endosc* 2004;18(12):1778-81.
4. Ahmad G, Duffy JMN, Watson AJS. Laparoscopic entry techniques and complications. *International Journal of Gynecology and Obstetrics* 2007;99(1):52-5.
5. Angelini L, Lirici MM, Papaspyropoulos V, Sossi FL. Combination of subcutaneous abdominal wall retraction and optical trocar to minimize pneumoperitoneum-related effects and needle and trocar injuries in laparoscopic surgery. *Surg Endosc* 1997;11(10):1006-1009.
6. Azevedo OC, Azevedo JL, Sorbello AA, Miguel GP, Wilson Junior JL, Godoy AC. Evaluation of tests performed to confirm the position of the Veress needle for creation of pneumoperitoneum in selected patients: a prospective clinical trial. *Acta Cir Bras* 2006;21(6):385-91.
7. Baggish MS. Analysis of 31 cases of major-vessel injury associated with gynecologic laparoscopy operations. *J Gynecol Surg* 2003;19(2):63-73.
8. Bateman BG, Kolp LA, Hoeger K. Complications of laparoscopy—operative and diagnostic. *Fertil Steril* 1996;66(1):30-35.
9. Bemelman WA, Dunker MS, Busch OR, Den Boer KT, de Wit LT, Gouma DJ. Efficacy of establishment of pneumoperitoneum with the Veress needle, Hasson trocar, and modified blunt trocar (TrocDoc): a randomized study. *J Laparoendosc Adv Surg Tech A* 2000;10(6):325-30.
10. Bhojrul S, Payne J, Steffes B, Swanstrom L, Way LW. A randomized prospective study of radially expanding trocars in laparoscopic surgery. *J Gastrointest Surg* 2000;4(4):392-397.
11. Bhojrul S, Vierra MA, Nezhat CR, Krummel TM, Way LW. Trocar injuries in laparoscopic surgery. *J Am Coll Surg* 2001;192(6):677-83.

12. Bishoff JT, Allaf ME, Kirkels W, Moore RG, Kavoussi LR, Schroder F. Laparoscopic bowel injury: incidence and clinical presentation. *J Urol* 1999;161(3):887–890.
13. Bonjer HJ, Hazebroek EJ, Kazemier G, Giuffrida MC, Meijer WS, Lange JF. Open versus closed establishment of pneumoperitoneum in laparoscopic surgery. *Br J Surg* 1997;84(5):599–602.
14. Briel JW, Plaisier PW, Meijer WS, Lange JF. Is it necessary to lift the abdominal wall when preparing a pneumoperitoneum? A randomized study. *Surg Endosc* 2000;14(9):862–864.
15. Brosens I, Gordon A, Campo R, Gordts S. Bowel injury in gynecologic laparoscopy. *J Am Assoc Gynecol Laparosc* 2003;10(1):9–13.
16. Byron JW, Markenson G, Miyazawa K. A randomized comparison of Verres needle and direct trocar insertion for laparoscopy. *Surg Gynecol Obstet* 1993;177(3):259–62.
17. Catarci M, Carlini M, Gentileschi P, Santoro E. Major and minor injuries during the creation of pneumoperitoneum. A multicenter study on 12,919 cases. *Surg Endosc* 2001;15(6):566–569 34. Schafer M, Lauper M, Krahenbuhl L. Trocar and Veress needle injuries during laparoscopy. *Surg Endosc* 2001;15(3):275–80.
18. Champault G, Cazacu F. Laparoscopic surgery: injuries caused by trocars. (French Survey 1994) in reference to 103,852 interventions. *J Chir (Paris)* 1995;132(3):109–13.
19. Chandler JG, Corson SL, Way LW. Three spectra of laparoscopic entry access injuries. *J Am Coll Surg* 2001;192(4):478–90.
20. Chapron C, Cravello L, Chopin N, Kreiker G, Blanc B, Dubuisson JB. Complications during set-up procedures for laparoscopy in gynecology: open laparoscopy does not reduce the risk of major complications. *Acta Obstet Gynecol Scand.* 2003;82(12):1125–9.
21. Chapron C, Fauconnier A, Goffinet F, Breart G, Dubuisson JB. Laparoscopic surgery is not inherently dangerous for patients presenting with benign gynaecologic pathology. Results of a meta-analysis. *Hum Reprod* 2002;17(5):1334–42.
22. Chapron C, Pierre F, Harchaoui Y et al. Gastrointestinal injuries during gynaecological laparoscopy. *Hum Reprod* 1999;14(2):333–7.
23. Chapron C, Pierre F, Querleu D, Dubuisson JB. Major vascular complications from gynecologic laparoscopy. *Gynecol Obstet Fertil* 2000;28(12):880–7.
24. Chapron C, Pierre F, Querleu D, Dubuisson JB. Complications of gynaecological laparoscopy. *Gynecol Obstet Fertil* 2001;29(9):605–12.
25. Chapron C, Querleu D, Bruhat MA et al. Surgical complications of diagnostic and operative gynaecological laparoscopy: a series of 29,966 cases. *Hum Reprod* 1998;13(4):867–72.
26. Chapron C, Querleu D, Mage G et al. Complications of gynecologic laparoscopy. Multicentric study of 7,604 laparoscopies. *J Gynecol Obstet Biol Reprod (Paris)* 1992;21(2):207–13.
27. Chapron CM, Pierre F, Lacroix S, Querleu D, Lansac J, Dubuisson JB. Major vascular injuries during gynecologic laparoscopy. *J Am Coll Surg* 1997;185(5):461–5.
28. Chin K, Newton J. Survey of training in minimal access surgery in the West Midlands region of the UK. *Gynacol Endosc* 1996;5(6):329–3.
29. Corson SL, Chandler JG, Way LW. Survey of laparoscopic entry injuries provoking litigation. *J Am Assoc Gynecol Laparosc* 2001;8(3):341–7.
30. Cravello L, Banet J, Agostini A, Bretelle F, Roger V, Blanc B. Open laparoscopy: analysis of complications due to first trocar insertion. French. *Gynecol Obstet Fertil* 2002;30(4):286–90.
31. Driscoll V. Bowel injury during laparoscopic sterilization – Vanessa Palmer v Cardiff and Vale NHS Trust. *The AvMA Med Legal J* 2004;10(3):109–111.
32. El Banna M, Abdel-Atty M, El Meteini M, Aly S. Management of laparoscopic-related bowel injuries. *Surg Endosc* 2000;14(9):779–82.
33. Ellis H. Medicolegal consequences of postoperative intraabdominal adhesions. *J R Soc Med* 2001;94(7):331–332.
34. Epstein J, Arora A, Ellis H. Surface anatomy of the inferior epigastric artery in relation to laparoscopic injury. *Clin Anat* 2004;17(5):400–08.
35. Ferriman A. Laparoscopic surgery: two thirds of injuries initially missed. *West J Med* 2000;173(6):372.
36. Fuller J, Ashar BS, Carey-Corrado J. Trocar-associated injuries and fatalities: an analysis of 1399 reports to the FDA. *J Minim Invasive Gynecol* 2005;12(4):302–07.
37. Galen DI, Jacobson A, Weckstein LN, Kaplan RA, DeNevi KL. Reduction of cannula-related laparoscopic complications using a radially expanding access device. *J Am Assoc Gynecol Laparosc* 1999;6(1):79–84.
38. Garry R. A consensus document concerning laparoscopic entry techniques: Middlesbrough, March 19–20 1999. *Gynacol Endosc* 1999;(8):403–406.



39. Geers J, Holden C. Major vascular injury as a complication of laparoscopic surgery: a report of three cases and review of the literature. *Am Surg* 1996;62(5):377-9.
40. Gett RM, Joseph MG. A safe technique for the insertion of the Hasson cannula. *ANZ J Surg* 2004;74(9):797-8.
41. Gordts S, Watrelot A, Campo R, Brosens I. Risk and outcome of bowel injury during transvaginal pelvic endoscopy. *Fertil Steril* 2001;76(6):1238-41.
42. Gunenc MZ, Yesildaglar N, Bingol B, Onalan G, Tabak S, Gokmen B. The safety and efficacy of direct trocar insertion with elevation of the rectus sheath instead of the skin for pneumoperitoneum. *Surg Laparosc Endosc Percutan Tech* 2005;15(2):80-81.
43. Hanney RM, Alle KM, Cregan PC. Major vascular injury and laparoscopy. *Aust N Z J Surg* 1995;65(7):533-35.
44. Harkki-Siren P, Kurki T. A nationwide analysis of laparoscopic complications. *Obstet Gynecol* 1997;89(1):108-12.
45. Harkki-Siren P, Sjoberg J, Kurki T. Major complications of laparoscopy: a follow-up Finnish study. *Obstet Gynecol* 1999;94(1):94-98.
46. Hart R, Doherty DA, Karthigasu K, Garry R. The value of virtual reality-simulator training in the development of laparoscopic surgical skills. *J Minim Invasive Gynecol* 2006;13(2):126-33.
47. Hasson HM. Open laparoscopy as a method of access in laparoscopic surgery. *Gynecol Endosc* 1999;8(6):353-62.
48. Hasson HM, Rotman C, Rana N, Kumari NA. Open laparoscopy: 29-year experience. *Obstet Gynecol* 2000;96(5 Pt 1):763-766.
49. Hender K. What is the safety of open (Hasson) technique versus closed (blind Veress needle) technique for laparoscopy? Centre for Clinical Effectiveness – Evidence Report. Centre for Clinical Effectiveness (CCE), Clayton, Victoria. 2001.
50. Hill DJ, Maher PJ. Direct cannula entry for laparoscopy. *J Am Assoc Gynecol Laparosc* 1996;4(1):77-79.
51. Hurd WW, Amesse LS, Gruber JS, Horowitz GM, Cha GM, Hurteau JA. Visualization of the epigastric vessels and bladder before laparoscopic trocar placement. *Fertil Steril* 2003;80(1):209-12.
52. Hurd WW, Bude RO, DeLancey JO, Newman JS. The location of abdominal wall blood vessels in relationship to abdominal landmarks apparent at laparoscopy. *Am J Obstet Gynecol* 1994;171(3):642-6.
53. Jacobson MT, Osias J, Bizhang R et al. The direct trocar technique: an alternative approach to abdominal entry for laparoscopy. *Journal of the Society of Laparoendoscopic Surgeons* 2002;6(2):169-74.
54. Jansen FW, Kapiteyn K, Trimbos-Kemper T, Hermans J, Trimbos JB. Complications of laparoscopy: a prospective multicentre observational study. *Br J Obstet Gynaecol* 1997;104(5):595-600.
55. Jansen FW, Kolkman W, Bakkum EA, de Kroon CD, Trimbos-Kemper TC, Trimbos JB. Complications of laparoscopy: an inquiry about closed- versus open-entry technique. *Am J Obstet Gynecol* 2004;190(3):634-638 *Surg Endosc* 2008; 22:2686-2697. 2693.
56. Jansen FW, Wind J, Cremeres JEL, Bemelman WA. 146: Entry Related Complications in Laparoscopy and Their Medical Liability Insurance. *J Minim Invasive Gynecol* 2007;14(6,1):S54-S55.
57. Kaali SG, Barad DH. Incidence of bowel injury due to dense adhesions at the sight of direct trocar insertion. *J Reprod Med* 1992;37(7):617-8.
58. Kaloo P, Cooper M, Molloy D. A survey of entry techniques and complications of members of the Australian Gynaecological Endoscopy Society. *Aust N Z J Obstet Gynaecol* 2002;42(3):264-6.
59. Kaloo P, Cooper M, Reid G. A prospective multicentre study of laparoscopic complications related to the direct-entry technique. *Gynaecol Endosc* 2002;11(2):67-70.
60. Kolkman W, Wolterbeek R, Jansen FW. Gynecological laparoscopy in residency training program: Dutch perspectives. *Surg Endosc* 2005;19(11):1498-1502.
61. Lalchandani S, Philips K. Laparoscopic entry technique-a survey of practices of consultant gynaecologists. *Gynecol Surg* 2005;2(4):245-49.
62. Larobina M, Nottle P. Complete evidence regarding major vascular injuries during laparoscopic access. *Surg Laparosc Endosc Percutan Tech* 2005;15(3):119-23.
63. Leng J, Lang J, Huang R, Liu Z, Sun D. Complications in laparoscopic gynecologic surgery. *Chin Med Sci J* 2000;15(4):222-6.
64. Leonard F, Lecuru F, Rizk E, Chasset S, Robin F, Taurelle R. Perioperative morbidity of gynecological laparoscopy. A prospective monocenter observational study. *Acta Obstet Gynecol Scand* 2000;79(2):129-134.
65. Lingam K, Cole RA. Laparoscopic entry port visited: a survey of practices of consultant gynaecologists in Scotland. *Gynaecol Endosc* 2001;10(5):335-42.
66. Mac CC, Lecuru F, Rizk E, Robin F, Boucaya V, Taurelle R. Morbidity in laparoscopic gynecological surgery: results of a prospective single-center study. *Surg Endosc* 1999;13(1):57-61.
67. Marret H, Golfier F, Cassagnol A, Raudrant D. Methods for laparoscopy: open laparoscopy or closed laparoscopy? Attitude of the French Central University Hospital. *Gynecol Obstet Fertil* 2001;29(10):673-9.

68. Marret H, Harchaoui Y, Chapron C, Lansac J, Pierre F. Trocar injuries during laparoscopic gynaecological surgery. Report from the French Society of Gynaecological Laparoscopy. *Gynecological Endoscopy* 1998;7(5):235-41.
69. Mayol J, Garcia-Aguilar J, Ortiz-Oshiro E, Diego Carmona JA, Fernandez-Represa JA. Risks of the minimal access approach for laparoscopic surgery: multivariate analysis of morbidity related to umbilical trocar insertion. *World J Surg* 1997;21(5):529-533.
70. McKernan JB, Champion JK. Access techniques: veress needle-initial blind trocar insertion versus open laparoscopy with the Hasson trocar. *Endosc Surg Allied Technol* 1995;3(1):35-8.
71. Merlin TL, Hiller JE, Maddern GJ, Jamieson GG, Brown AR, Kolbe A. Systematic review of the safety and effectiveness of methods used to establish pneumoperitoneum in laparoscopic surgery. *Br J Surg* 2003;90(6):668-79.
72. Merlin TL, Hiller JE, Maddern GJ, Jamieson GG, Brown AR, Kolbe A (2001) A systematic review of the methods used to establish laparoscopic pneumoperitoneum. ASERNIP-S Report No. 13. Adelaide, South Australia: ASERNIP-S. <http://www.surgeons.org/asernip-s>. 2001.
73. Moberg AC, Montgomery A. Primary access-related complications with laparoscopy: comparison of blind and open techniques. *Surg Endosc* 2005;19(9):1196-99.
74. Molloy D, Kaloo PD, Cooper M, Nguyen TV. Laparoscopic entry: a literature review and analysis of techniques and complications of primary port entry. *Aust N Z J Obstet Gynaecol* 2002;42(3):246-254.
75. Munro MG. Laparoscopic access: complications, technologies, and techniques. *Curr Opin Obstet Gynecol* 2002;14(4):365-74.
76. Narendran M, Baggish MS. Mean Distance Between Primary Trocar Insertion Site and Major Retroperitoneal Vessels During Routine Laparoscopy. *J Gynecol Surg* 2002;18(4):121-7.
77. Nezhat C, Childers J, Nezhat F, Nezhat CH, Seidman DS. Major retroperitoneal vascular injury during laparoscopic surgery. *Hum Reprod* 1997;12(3):480-3.
78. Nezhat CH, Nezhat F, Brill AI, Nezhat C. Normal variations of abdominal and pelvic anatomy evaluated at laparoscopy. *Obstet Gynecol* 1999;94(2):238-42.
79. Nezhat FR, Silfen SL, Evans D, Nezhat C. Comparison of direct insertion of disposable and standard reusable laparoscopic trocars and previous pneumoperitoneum with Veress needle. *Obstet Gynecol* 1991;78(1):148-150.
80. Nordestgaard AG, Bodily KC, Osborne RW Jr., Buttorff JD. Major vascular injuries during laparoscopic procedures. *Am J Surg* 1995;169(5):543-5.
81. Pasic RP, Kantardzic M, Templeman C, Levine RL. Insufflation techniques in gynecologic laparoscopy. *Surg Laparosc Endosc Percutan Tech* 2006;16(1):18-23.
82. Phillips PA, Amaral JF. Abdominal access complications in laparoscopic surgery. *J Am Coll Surg* 2001;192(4):525-36.
83. Rahman MM, Mamun AA. Direct trocar insertion: alternative abdominal entry technique for laparoscopic surgery. *Mymensingh Med J* 2003;12(1):45-7.
84. RANZCOG. Use of the Veress needle to obtain pneumoperitoneum prior to laparoscopy. Statement C-Gyn 7. Consensus statement of the Royal Australian and New Zealand College of Obstetricians and Gynaecologists (RANZCOG), the Australian Gynaecological Endoscopy Society (AGES). Royal Australian and New Zealand College of Obstetricians and Gynaecologists, Australia. 2006.
85. Reich H, Rasmussen C, Vidali A. Peritoneal hyperdistention for trocar insertion. *Gynecological Endoscopy* 1999; 8(6):375-77.
86. Reich H, Ribeiro SC, Rasmussen C, Rosenberg J, Vidali A. High-pressure trocar insertion technique. *JLS* 1999; 3(1):45- 48.
87. Rein H. Complications and litigation in gynecologic endoscopy. *Curr Opin Obstet Gynecol* 2001;13(4):425-9.
88. Rosen DM, Lam AM, Chapman M, Carlton M, Cario GM. Methods of creating pneumoperitoneum: a review of techniques and complications. *Obstet Gynecol Surv* 1998;53(3):167-74.
89. Roviato GC, Varoli F, Saguatti L, Vergani C, Maciocco M, Scarduelli A. Major vascular injuries in laparoscopic surgery. *Surg Endosc* 2002;16(8):1192-6.
90. Roy GM, Bazzurini L, Solima E, Luciano AA. Safe technique for laparoscopic entry into the abdominal cavity. *J Am Assoc Gynecol Laparosc* 2001;8(4):519-28.
91. Saber AA, Meslemani AM, Davis R, Pimentel R. Safety zones for anterior abdominal wall entry during laparoscopy: a CT scan mapping of epigastric vessels. *Ann Surg* 2004; 239(2):182-5.
92. Saville LE, Woods MS. Laparoscopy and major retroperitoneal vascular injuries (MRVI). *Surg Endosc* 1995;9(10):1096-1100.
93. Schrenk P, Woisetschlager R, Rieger R, Wayand W. Mechanism, management, and prevention of laparoscopic bowel injuries. *Gastrointest Endosc* 1996;43(6):572-4.
94. Soderstrom RM. Bowel injury litigation after laparoscopy. *J Am Assoc Gynecol Laparosc* 1993;1(1):74-7.

95. Soderstrom RM. Injuries to major blood vessels during endoscopy. *J Am Assoc Gynecol Laparosc* 1997;4(3): 395–8.
96. Sokol AI, Chuang K, Milad MP. Risk factors for conversion to laparotomy during gynecologic laparoscopy. *J Am Assoc Gynecol Laparosc* 2003;10(4):469–73.
97. Sriprasad S, Yu DF, Muir GH, Poulsen J, Sidhu PS. Positional anatomy of vessels that may be damaged at laparoscopy: new access criteria based on CT and ultrasonography to avoid vascular injury. *J Endourol* 2006;20(7):498–503.
98. Sutton CJ. Medico-legal implications of keyhole surgery. *Medico-Legal J* 1996;64(Pt 3):101–13.
99. Sutton CJG, Philips K. Preventing Gynaecological Laparoscopic Injury. Guideline No. 2007;48.
100. Teoh B, Sen R, Abbott J. An evaluation of four tests used to ascertain Veres needle placement at closed laparoscopy. *J Minim Invasive Gynecol* 2005;12(2):153–8.
101. Ternamian AM. Laparoscopy without trocars. *Surg Endosc* 1997;11(8):815–18.
102. Ternamian AM, Deitel M. Endoscopic threaded imaging port (EndoTIP) for laparoscopy: experience with different body weights. *Obes Surg* 1999;9(1):44–7.
103. Tsaltas J, Pearce S, Lawrence A, Meads A, Mezzatesta J, Nicolson S. Safer laparoscopic trocar entry: It's all about pressure. *Aust N Z J Obstet Gynaecol* 2004;44(4):349–50.
104. Vilos AG, Vilos GA, Abu-Rafea B, Hollett-Caines J, Al Omran M. Effect of body habitus and parity on the initial Veres intraperitoneal CO<sub>2</sub> insufflation pressure during laparoscopic access in women. *J Minim Invasive Gynecol* 2006; 13(2):108–13.
105. Vilos GA. Litigation of laparoscopic major vessel injuries in Canada. *J Am Assoc Gynecol Laparosc* 2000;7(4):503–09.
106. Vilos GA (2002) Laparoscopic bowel injuries: forty litigated gynaecological cases in Canada. *J Obstet Gynaecol Canada: JOGC* 24(3):224–30.
107. Vilos GA, Ternamian A, Dempster J, Laberge PY. Laparoscopic entry: a review of techniques, technologies, and complications. Society of Obstetricians and Gynaecologists of Canada Clinical Practice Guideline. *J Obstet Gynaecol Can* 2007;29(5):433–47.
108. Wang PH, Lee WL, Yuan CC et al. Major complications of operative and diagnostic laparoscopy for gynecologic disease. *J Am Assoc Gynecol Laparosc* 2001;8(1):68–73.
109. Wind J, Cremers JE, Berge Henegouwen MI, Gouma DJ, Jansen FW, Bemelman WA. Medical liability insurance claims on entry-related complications in laparoscopy. *Surg Endosc* 2007;5.
110. Woolcot R. The efficacy and safety of different techniques for trocar insertion in laparoscopic surgery. *Minim Invasive Ther Allied Technol* 2001;10(1):11–14.
111. Yim SF, Yuen PM. Randomized double-masked comparison of radially expanding access device and conventional cutting tip trocar in laparoscopy. *Obstet Gynecol* 2001;97(3):435–38.